

CHRONIC OSTEOMYELITIS

**A BONE INFECTION CASE TREATED
WITH CLASSICAL HOMEOPATHIC
MEDICINE**

ABOUT THE AUTHOR

Dr Vikas Singhal, B.Sc., D.N.H.E., B.H.M.S, M.Sc.

(Microbiology)

Founder Director: Dr. Singhal Homeo Clinic (Since 2004)

Founder Director: Homeo Saga Pvt. Ltd. International (Since 2024)

Address: #2732, Sector 38 – C, Chandigarh, India

Email: drvikassinghal38@gmail.com

Mobile No: +91 – 708 746 2000

+91 – 78971 78971



ABSTRACT

- ***Osteomyelitis*** refers to a contagion in the bone, often triggered by *Staphylococcus aureus*, however other bacteria and fungi can also be responsible.
- ***Homeopathy*** offers a complete approach that emphasizes the body's immune system, encouraging bone healing, and handling both acute and chronic phases of the disease.
- It is well recognized that ***homeopathy*** has completely cured osteomyelitis particularly in cases with persistent pus discharge from sinuses that have not responded to antibiotics.
- In this paper we have discussed in detail how ***homeopathy*** helps in curing ***osteomyelitis***.

KEYWORDS: Osteomyelitis, Bone Healing, Pus Discharge, Immune System, Acute And Chronic Bone Disease, Homeopathic Medicines Etc.



WHAT IS OSTEOMYELITIS.!?



- ***Osteomyelitis is a serious infection of the bone.*** Although many people do not hear much about it, osteomyelitis can have a strong effect on everyday life if it is not treated properly.
- **Treating infections in the bone is often difficult because bones do not get as much blood flow as other parts of the body. As a result, healing can take longer and may require careful, ongoing treatment.**
- **For many patients, osteomyelitis is not a short-term problem.**
- **Treatment may continue for several weeks or even months.**
- **Regular hospital visits, long courses of medicines, and sometimes surgery can leave patients feeling tired, stressed, and emotionally drained.**
- **Family members are also affected, as they support their loved ones through pain, limited movement, and worries about recovery.**
- **Even after the infection improves, some people continue to notice pain, stiffness, or weakness in the affected area.**





- **Because of this, early diagnosis and proper medical care are very important. Starting treatment at the right time helps control the infection, protect the bone, and reduce the chances of long-term problems.**
- **Standard medical treatment, including antibiotics and surgery when needed, is essential and should never be delayed.**
- **At the same time, many patients look for additional ways to feel more comfortable, manage pain, and support healing.**
- **This is where supportive and integrative approaches, such as homeopathy, may be used alongside conventional care.**
- **When used responsibly and under medical supervision, homeopathy can be considered as a complementary approach alongside standard treatment, with the aim of improving comfort, overall well-being, and quality of life.**

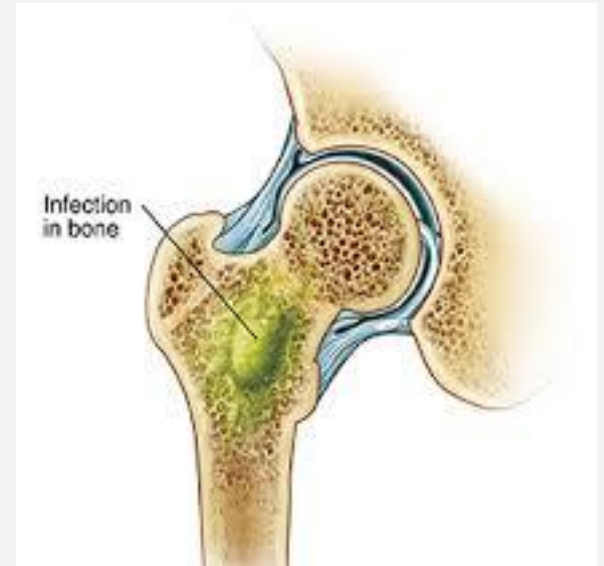

SYMPTOMS OF OSTEOMYELITIS

- Discomfort
- Fever
- Temperature
- Inflammation
- Tiredness
- Restricted Movement
- Soreness
- Reddishness
- Chills
- Pus or discharge from a wound or surgery site.

DIAGNOSIS OF OSTEOMYELITIS

- Ways to diagnose Osteomyelitis:
 - Physical Exam
 - CBC (Complete Blood Count)
 - ESR & CRP
 - Blood Cultures
 - X-rays
 - MRI (Magnetic Resonance Imaging)
 - Bone Scan (Scintigraphy)
 - CT Scan
 - Bone Biopsy (Aspirate)





AIM & OBJECTIVES



AIM:

- To put light and importance of wholistic and integrated medicine for the treatment of chronic osteomyelitis.
- To provide the complete information about the case of a patient suffering from osteomyelitis and bone tuberculosis getting completely cured from homeopathic medicine.



OBJECTIVES:

- To provide insights about an osteomyelitis case completely cured with classical homeopathic medicine.
- To promote the idea of wholistic and integrative medicine for the treatment of osteomyelitis.

+ COURSE OF TREATMENT BY DR. SINGHAL

- **8th March 2022: Analysis Of Symptoms And Selection Of Medicine** : So as per the characteristic symptoms like deep suppurations with deep yellow thick and bloody pus and injuries which are slow to heal were showing as **calcareea sulph** And **silicea** as the major medicines but when we entered hectic fever with burning of soles and warm room aggravates. **Calcareea sulphurica** wins the battle. As patient was a hot patient and everything was pointing towards **calcareea sulph**. So, we decided to start with the indicated Similimum medicine. First medicine prescribed was **Calcareea sulph** 1M. For the first day of the month then followed by sugar of milk (Rubrum) For next 3 months.
- **10th June 2022 to 6th March 2024** : After second examination medicine prescribed was Gun powder 30 in 5 drops once daily for 6 months followed by only sugar of milk for next 6 months.
- **7th March 2024 till 30 June 2024** : During third examination the same medicine was prescribed Again i.e. Gunpowder 200 potency was given in 5 drops just once daily for 3 months. Followed by sugar of milk (Sac lac) for next 9 months.
- **JULY 2024 TILL 27TH MARCH 2025** : During fourth examination everything was clear in terms of infection and patient was healthy so only Pure Sugar Of Milk was prescribed.

REPERTORY SHEET

Grade ▾

Waffle graph ▾ Go to Remedy

synergy

Total Rubrics Kingdom

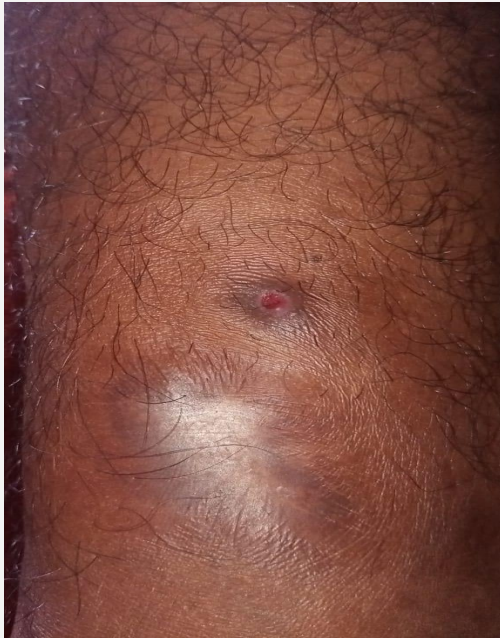	Calcphs.	Sil.	sulph.	Hep.	Merc.	Puls.	Carb-v.	Lach.	Calc.	Sep.	Lyc.	Caut.	Graph.	Phos.	Ars.	Carbn-s.	Croc.	Iod.	Kall-s.	Mez.	Nit-ac.
Total	13	15	12	11	10	15	11	9	8	8	11	8	8	8	7	7	7	7	7	7	7
Rubrics	8	6	6	6	6	5	5	5	5	5	4	4	4	4	4	4	4	4	4	4	4
Kingdom	Blue	Blue	Blue	Blue	Blue	Green	Blue	Red	Blue	Red	Green	Blue	Blue	Blue	Blue	Blue	Green	Blue	Blue	Green	Blue

R.R. - Generalities; Abscesse... (7)	Light Blue	Light Blue	White	White	White	White	White	White	White	White	White	White	White	White	White	White	White	White	White	White	White
R.R. - Generalities; Abscess... (46)	Light Blue	Purple	Blue	Black	Black	Purple	Purple	Blue	White	Blue	Purple	Purple	Light Blue	Blue	Black	White	Light Blue	Light Blue	White	Light Blue	Purple
R.R. - Generalities; Abscess... (32)	Blue	Black	Light Blue	Blue	Light Blue	Blue	White	White	Light Blue	Light Blue	White	White	White	White	White	Light Blue	White	White	Light Blue	Light Blue	White
R.R. - Generalities; Injuries (... (17)	Light Blue	Blue	Light Blue	Blue	Light Blue	White	Light Blue	Light Blue	White	White	White	White	White	White	White	White	White	White	White	White	Light Blue
R.R. - Skin; Ulcers; discharg... (57)	Light Blue	Light Blue	Light Blue	Blue	Purple	Blue	White	Blue	Blue	Light Blue	Blue	Light Blue	Light Blue	Blue	Light Blue	Light Blue	Light Blue	Light Blue	Light Blue	Purple	Blue
R.R. - Extremities; Pain; bur... (130)	Purple	Purple	Black	Light Blue	Light Blue	Purple	Purple	Black	Purple	Light Blue	Black	Blue	Purple	Light Blue	Blue	Light Blue	Light Blue	Light Blue	Blue	White	White
R.R. - Extremities; Pain; burni... (1)	Light Blue	White	White	White	White	White	White	White	White	White	White	White	White	White	White	White	White	White	White	White	White
R.R. - Generalities; Warm; r... (149)	Purple	White	Purple	Light Blue	Light Blue	Black	Blue	Light Blue	Light Blue	Blue	Purple	Light Blue	Purple	Blue	Light Blue	Purple	Black	Black	Purple	Blue	Light Blue

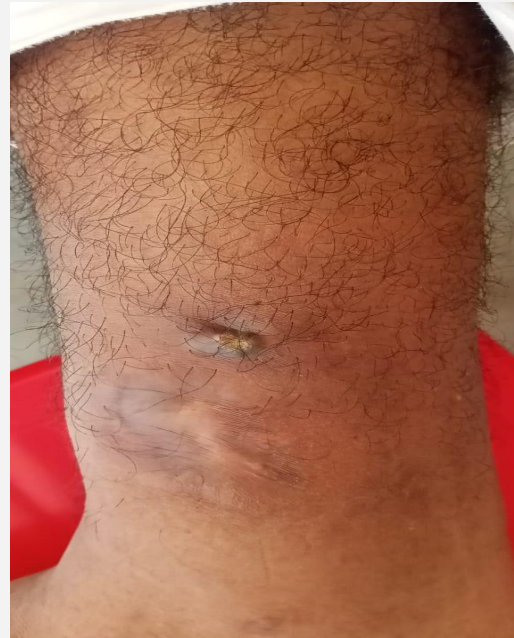Calcarea sulphurica



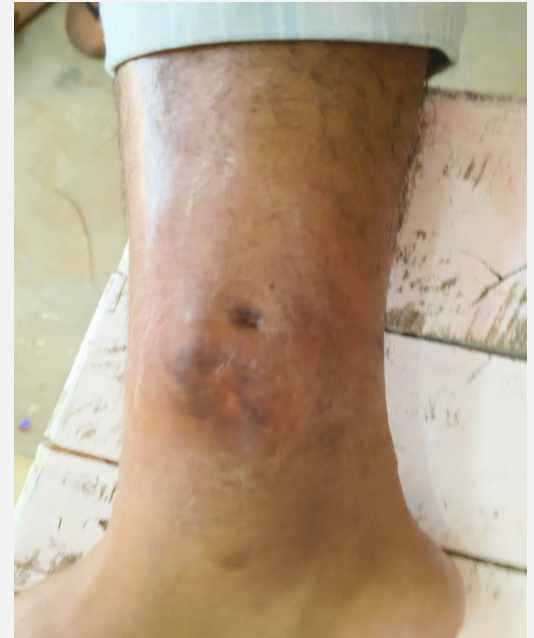IMAGES OF RECOVERY



INITIAL



DURING TREATMENT



AFTER TREATMENT



DISCUSSION

Since April 2025 till date patient is totally deprived of medicines means no medicine and the final MRI report is taken in the month of January 2026 which is finally showing the total Bony union of the distal end of tibia with just minimal fluid signals and mild inflammatory changes but any abnormality was ruled out with normal CBC, ESR and CRP quantitative blood test.

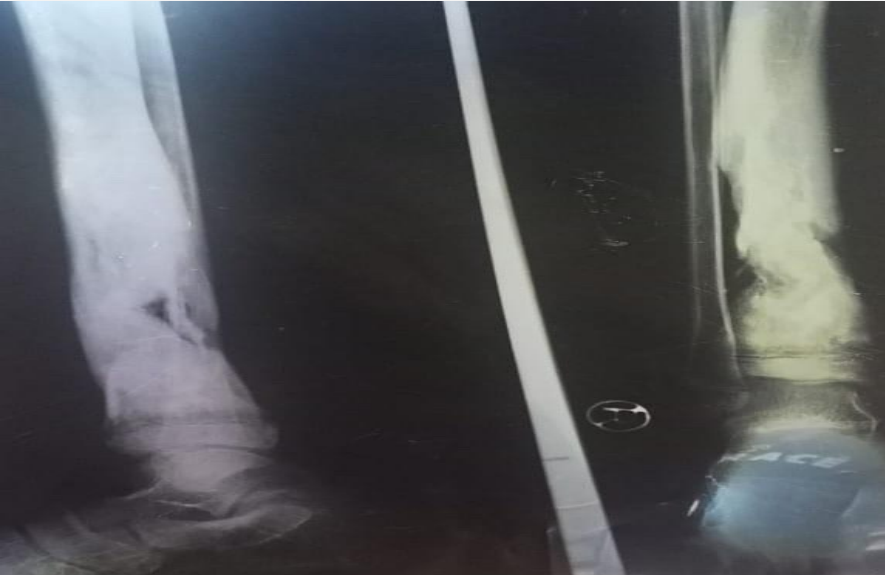RECOMMENDED DIET

- Balanced anti-inflammatory and bone-reinforcement diet can help in aiding the immune system, decreasing inflammation, and recovering bone health. Following diet was recommended during the course of treatment:
- Warm Lemon Water or Turmeric Tea which helps in Detoxification
- Oats with chia seeds, flaxseeds, honey, and berries or Ragi
- Herbal tea or green tea, Buttermilk or coconut water
- Yogurt with flaxseeds, fresh fruits
- Brown rice, dal (lentils), steamed vegetables, and paneer/tofu
- Stir-fried vegetables with tofu and quinoa or khichdi

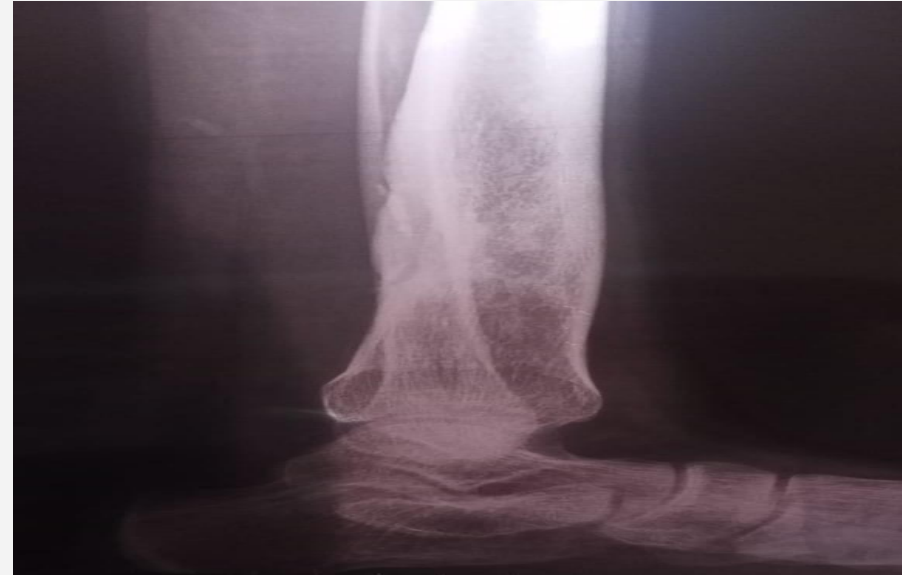
+ OBSERVATION ON X-RAY

From the X-Ray Imaging before treatment, it can be clearly seen that the leg bone is not in union. After the treatment it can be clearly seen that the bones are now in union & there is no infection. Blood flow is also normal. There is a **SIGNIFICANT AND MAJOR IMPROVEMENT** between the X – Ray done before treatment and X – Ray done after treatment.

BEFORE TREATMENT

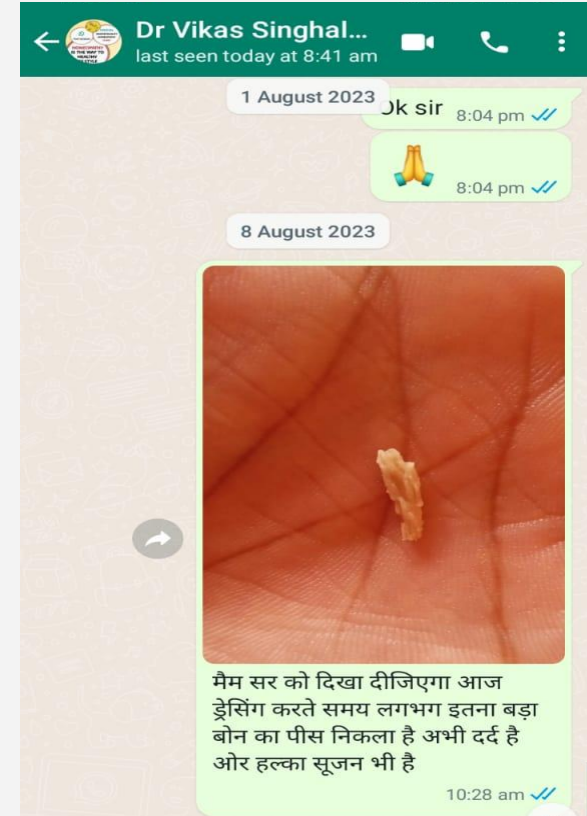

AFTER TREATMENT



TURNING POINT OF THE CASE

- During the course of treatment, a bone piece came out from the spot of infection, this shows that this stuck bone piece was the main cause of infection and during the treatment this bone piece came out and the patient's condition got normal.
- This is the TURNING POINT of this case, actually, the biggest bone piece came out gradually and slowly with the help of medicine only.





ADVANCE DIAGNOSTIC CENTRE

Near- Satyendra Guest House Malviya Road- BASTI

Mob. : 7307632993, 7985849759, 7860306876

adcbasti786@gmail.com | Website : www.bastiladc.com



PATIENT NAME	MR.ABHISHEK KUMAR	PATIENT ID	170202
AGE/SEX	24 YRS./ MALE	DATE	17-Feb-24
REF DOCTOR	DR.VIKASH SINGHAL		

NCCT RT.LEG

OBSERVATIONS:

Small lytic lesion measuring approx. 7x3x8mm seen in medullary cavity of distal tibia left shaft with cortical breach at posterior aspect with diffuse adjacent cortical thickening, suggestive of partially united fracture with ? focal osteitis.

Diffuse osteopenia noted.

Otherwise visualized bones are normal.

No dislocation / subluxation seen.

No evidence of any congenital abnormality.

No joint effusion is seen.

Joint spaces are normal.

IMPRESSION:

- Small lytic lesion in medullary cavity of distal tibia left shaft with cortical breach at posterior aspect with diffuse adjacent cortical thickening, suggestive of partially united fracture with ? focal osteitis.
- Diffuse osteopenia.
- Adv:- MRI Tibia will be more informative.

Chetan Garg

DR CHETAN GARG
MBBS, DNB
Consultant Radiologist
RMC REG NO :- 31607

BEFORE HOMEOPATHIC TREATMENT

Emergency Services For 24 Hours

- The Radiological Diagnosis is based on the interpretation of various shadows produced by both normal and abnormal tissues and are not always conclusive.
- This report/film is for persual of Doctor only not for Medico-Legal cases.
- Clinical co-relation is essential for final diagnosis in case of any discrepancy with clinical profile. Please contact the centre immediately. Not for Medico Legal Purpose

NAME: MR. ABHISHEK KUMAR

AGE/SEX: 24 Y/M

REF. BY: DR. D.K GUPTA

DATE: 12/01/2026

MRI RIGHT LEG

Findings

Bones:

- Evidence of an **old irregular fracture line involving the distal end of the tibia. Bony union is noted**, however the fracture margins appear irregular. **Altered bone alignment** is seen at the fracture site, suggestive of **mild malalignment.**

Post-operative Tract:

Minimal fluid signal is noted along the post-operative tract, which may represent **mild inflammatory changes.**

Soft Tissues:

- **Mild surrounding soft tissue edema/inflammatory changes** are present adjacent to the post-operative region.
No evidence of deep soft tissue abscess.
No abnormal muscle edema or necrosis.

Neurovascular Structures:

- Appear unremarkable in the visualized segments.

• Impression

- **Healed old distal tibial fracture** with evidence of **bony union**, associated with **mild malalignment.**

Post-operative changes along the posterior aspect of the tibia with **minimal fluid along the surgical tract**, likely representing **low-grade inflammatory changes/superimposed mild infection**

No definite abscess or acute collection identified.

Post-operative tract infection cannot be entirely excluded; recommend clinical correlation and laboratory markers (CRP, ESR, TLC) for further evaluation.

AFTER HOMEOPATHIC TREATMENT

Isra Khan

Dr. Isra Khan
MBBS MD
Radiologist

MRI AFTER TREATMENT (12-01-2026)



MRI RIGHT LEG : Findings:

Bones:

Evidence of an old irregular fracture line involving the distal end of the tibia. Bony union is noted; however, the fracture margins appear irregular. Altered bone alignment is seen at the fracture site, suggestive of mild malalignment.

Post-operative Tract:

Minimal fluid signal is noted along the post-operative tract, which may represent mild inflammatory changes.

Soft Tissues:

Mild surrounding soft tissue edema/inflammatory changes are present adjacent to the post-operative region. No evidence of deep soft tissue abscess. No abnormal muscle edema or necrosis.

Neurovascular Structures:

Appear unremarkable in the visualized segments.

Impression:

Healed old distal tibial fracture with evidence of bony union, associated with mild malalignment. Post-operative changes along the posterior aspect of the tibia with minimal fluid along the surgical tract, likely representing low-grade inflammatory changes/superimposed mild infection.



PATIENT'S REVIEW

The review of the patient is as follows:

- As I was not very aware of the situation, in March 2020 I opted for some local homeopathic doctor who advised me to take silica in 1M potency continuously for 1 year and 9 months. Along with ATT that is Anti Tuberculosis treatment, and my situation deteriorated further while taking this medicine.
- Then I contacted Dr Singhal Homeopathy in Chandigarh on 08th march 2022 and taken the prescribed medicine from time to time, and done the tests regularly, I followed up regularly and everything became normal and my leg got completely cured in 3 years, neither any operation was done nor all my problems of patients was solved sitting at home. Now I am able to walk normally and with the help of Homeopathy this was possible thanks to Dr. Vikas Singhal of Dr Singhal Homeopathy, Clinic.

CONCLUSION

- **Actually the history of the case was very different from a any other osteo myelitis case so this case was totally destroyed & mis-diagnosed and mis-treated and after losing all hope the patient switched to classical homeopathy medicine.**
- **Scan report taken in the month of January 2026 along with all types of blood reports like CBC TLC and CRP are supportive for the total cure of chronic osteomyelitis in this patient.**
- **After successfully treating this case in Dr. Singhal Homeopathic Clinic Chandigarh, we can proudly conclude that Homeopathic medicines can completely treat chronic osteomyelitis cases and also bone tuberculosis as homeopathy works on the principle of finding out the similar and the most peculiar characteristic symptom and prescribing the medicine on the basis of Genetic Constitutional Similimum (G.C.S.).**
- **It's really a question of concern here that how many people suffering from chronic osteomyelitis or other types of bone infection throughout the world can get a ray of hope in homeopathy without using surgeon's knife, we can proudly say that yes, we can save such patients from deterioration if they come to us in earlier stages of the disease. And that is why dr. Vikas Singhal is of the opinion of integrative wholistic medicine.**



Homeopathy for Osteomyelitis Treatment

Holistic healing

Reduces inflammation



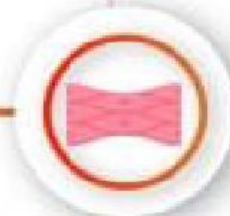Promotes bone regeneration



Boosts immunity



Supports tissue repair



Dr. Singh
Homeopathy TM

REFERENCES

1. Lew DP, Waldvogel FA. Osteomyelitis. *The Lancet*, 2004;364(9431):369–379.
2. Hatzenbuehler J, Pulling TJ. Diagnosis and management of osteomyelitis. *American Family Physician*, 2011;84(9):1027–1033.
3. Stat Pearls Publishing. Osteomyelitis. In: *Stat Pearls [Internet]*. Treasure Island (FL): Stat Pearls Publishing; 2024.
4. Medscape. Osteomyelitis: Overview, pathophysiology, clinical features, and management.
5. MSD Manual Professional Edition. Osteomyelitis.
6. MedlinePlus. Osteomyelitis. U.S. National Library of Medicine.
7. Pineda C, Espinosa R, Pena A. Radiographic imaging in osteomyelitis: The role of X-ray, CT, and MRI. *Seminars in Plastic Surgery*, 2009;23(2):80–89.
8. Annals of Homeopathic Research. Homoeopathic approach to osteomyelitis with its pathological significance.
9. International Journal of Scientific Research (IJSR). Treatment of osteomyelitis with individualized homoeopathic medicine: A case report. 2023.
10. Materia Medica by William Boericke.

REFERENCES

11. Boer Icke's New Manual of Homeopathic Materia Medica with Repertory: Third Revised & Augmented Edition Based on Ninth Edition.
12. Harrison's Principal of Internal Medicines. 17th Ed.
13. Davidsons Principal & practice of Medicines.
14. Kent JT. Repertory of Homoeopathic Materia Medica.
15. Dubey SK. Text book of Material Medica.
16. Choudhari NM. A study on Materia Medica.
17. Boericke W. Pocket Manual of Homoeopathic Materia Medica & Repertory.
18. Allen HC. Keynotes & characteristics with comparisons of some leading remedies of The Materia Medica with Bowel Nosodes. 8th ed.
19. Uniyal P, Kinra R. Materia Medica for Students.
20. Dr. S. K. Dubey, Text Book Of Material Medica.



BIOGRAPHY

- ❑ **Dr. Vikas Singhal** (drvikassinghal38@gmail.com,+91-78971 78971) is a classical homeopath with over two decades of experience, treating patients from 70+ countries.
- ❑ His expertise in managing chronic viral and autoimmune disorders, including HPV-related and syphilitic infections, reflects the power of homeopathy as a holistic, natural system of healing.
- ❑ He is one of the best **Homeopathic Physicians** to treat acute & chronic, recurring, autoimmune, and resistant diseases in the **Tricity & India**.
- ❑ He is offering treatment for various **rare, chronic and incurable diseases** considered incurable in other systems of medicines to Indian Patients and patients from different parts of the world.
- ❑ Dr. Singhal is known for his individualized, evidence-based approach to treatment. His commitment to evidence-based, classical homeopathic practice has earned him respect and recognition which also earned him several honors and awards for his selfless service to mankind, he is the recipient of prestigious **Bharat Shri Award (2025)**.
- ❑ Dr. Singhal is a **Life Member** of leading professional bodies like the **Indian Institute of Homeopathic Physicians (IIHP), Akhil Bhartiya Chikitsak Association (ABCA), Liga Medicorum Homoeopathica Internationalis (LMHI), and the Australian Homeopathic Association (International Allied Member Practitioner)**.



+ OUR PUBLISHED CASE

We are glad and proud to share that a successfully treated case of osteomyelitis by our team has been published successfully in the “EUROPEAN JOURNAL OF PHARMACEUTICAL AND MEDICAL RESEARCH” . The link for visiting and reading the article is provided below:
<https://zenodo.org/records/18875192>



EJPMR, 2026, 13(3), 365-371

Research Article

Impact Factor: 8.15

EUROPEAN JOURNAL OF PHARMACEUTICAL
AND MEDICAL RESEARCH

www.ejpmr.com

ISSN (O): 2394-3211

ISSN (P): 3051-2573

Coden USA: EJPMAJ

OSTEOMYELITIS AND SCOPE OF HOMEOPATHY

Dr. Vikas Singhal*

Director, Dr. Singhal Homeo, Director, Homeo Saga Pvt. Ltd. Chandigarh, India.



*Corresponding Author: Dr. Vikas Singhal

Director, Dr. Singhal Homeo, Director, Homeo Saga Pvt. Ltd. Chandigarh, India.

DOI: <https://doi.org/10.5281/zenodo.18875192>



How to cite this Article: Dr. Puratchi Kodi A.* (2026). Osteomyelitis and Scope of Homeopathy. European Journal of Pharmaceutical and Medical Research, 13(3), 365-371.

This work is licensed under Creative Commons Attribution 4.0 International license.

Article Received on 05/02/2026

Article Revised on 25/02/2026

Article Published on 01/03/2026

ACKNOWLEDGEMENT & THANKS!

- I would like to express my **sincere** and **heartfelt gratitude** to the **patient** and their family for their trust, patience, and cooperation throughout the course of this case. Their willingness to share their journey has been invaluable.
- I am **deeply thankful** to all my **mentors** and **colleagues** whose guidance, support, and clinical insights greatly contributed to the understanding and management of this case of **Chronic Osteomyelitis**. Their continuous encouragement and dedication have played a significant role.
- A special note of **Thanks** to the audience for their patience, time, and attentive listening. Your presence and engagement are truly appreciated.
- Lastly, I feel honored and grateful for the opportunity to present this case before you all. **Thank you.**
- For any query, feel free to contact **Dr. Singhal** via WhatsApp on **+91 7087463000** or you can drop a mail at **drvikassinghal38@gmail.com**



THANK YOU